


## EP CASE REPORT

# Cryoablation of stellate ganglion for the management of electrical storm: the first reported case

Sofia Chatzidou<sup>1</sup>, Christos Kontogiannis <sup>1\*</sup>, Konstantinos Tampakis<sup>1</sup>, Eleni Episkopou<sup>2</sup>, Ioannis Kanakakis<sup>1</sup>, and Ioannis Paraskevaidis<sup>1</sup>

<sup>1</sup>Department of Clinical Therapeutics, "Alexandra" Hospital, School of Medicine, National and Kapodistrian University of Athens, 80 Vassilisis Sofias str, Athens, Greece; and <sup>2</sup>Metropolitan General Hospital, Athens, Greece

\* Corresponding author. Tel: +30 213 2162087; fax: +30 210 3381478. E-mail address: kont\_chr@hotmail.com

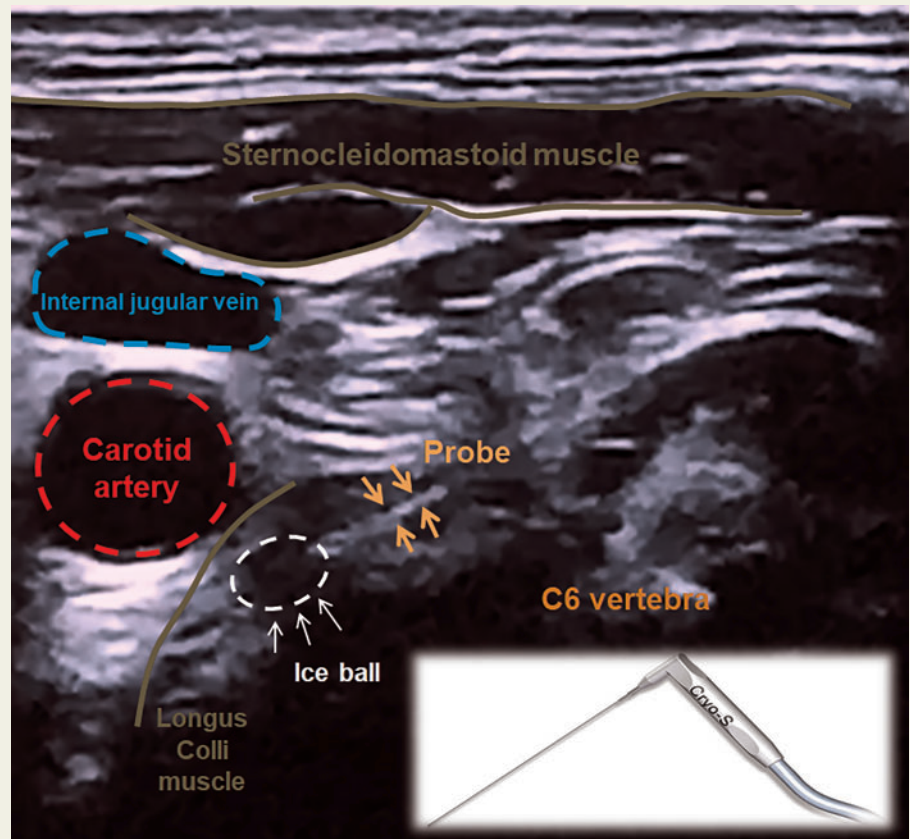
### Case presentation

A 64-year-old man presented due to electrical storm (ES) and recurrent implantable cardioverter-defibrillator (ICD)—discharges. Patient's medical history included an inferior myocardial infarction, chronic ischaemic cardiomyopathy, ICD implantation for secondary prevention of ventricular tachycardias (VTs), upgraded to cardiac resynchronization therapy with defibrillator, and previous VT ablation. At this point, he was under antiarrhythmic treatment with mexiletine and carvedilol, as he discontinued amiodarone due to thyrotoxicosis.

Initial management with escalation of antiarrhythmic treatment to intravenous esmolol and xylocaine, reprogramming of the device to a long detection interval combined with antitachycardia pacing during charging, general anaesthesia and intubation were mildly effective in reducing VT episodes and shocks.

Interventional sympathetic blockade was decided as a step by step approach. Blockade of the left stellate ganglion blockade (LSGB) with continuous infusion of 0.2% ropivacaine terminated ES without completely ending VT events (five episodes in following 7 days). Taking into consideration the response to LSGB, a novel technique of cryoneurolysis of the left stellate ganglion (LSG) was attempted to achieve a long-term autonomic modulation.

Placing the patient in a 45-degree semi-Fowler's position under a sterile condition, the C6 root level was identified by lateral approach with ultrasound guidance (Figure 1). The needle was inserted towards the left Chassaignac's tubercle using plane technique, to reach the prevertebral fascia on the top of longus Colli muscle and one cryoapplication of 3 min duration was delivered ( $-78^{\circ}\text{C}$ ), using carbon dioxide as a coolant pressurized gas (CRYO-S Painless device, Metrum). No procedural complications were observed except transient Horner



**Figure 1** Cryoablation of the left stellate ganglion with ultrasound guidance. At the C6 vertebra level, the probe (down and right) reaches the prevertebral fascia on the top of Longus Colli muscle. One cryoapplication of 3 min duration is delivered ( $-78^{\circ}\text{C}$ ) and an ice-ball is seen forming in tissue at the tip of the cryoneurolysis trocar.

Syndrome. Patient discharged the hospital electrically stable and remained free of VT events for 5 months, performing monthly follow-up visits with device interrogation.

### Discussion

Cardiac sympathetic blockade is a cornerstone in the management of ES. Several interventions have been developed, when conventional treatment with b-blockers fails, including LSGB, renal denervation, and cardiac sympathetic denervation.<sup>1</sup> To the best of our knowledge, this is the first report of LSGB with the novel technique of cryoneurolysis.

Targeted injection of a local anaesthetic near the LSG provides sympathetic blockade, while infusion through a continuous nerve block catheter achieves a longer-acting suppression of ventricular arrhythmias.<sup>2</sup> Cryoneurolysis is a non-pharmacologic technique that has been introduced in the management of pain originating from sensory nerves.<sup>3</sup> Taking into account the efficacy of local anaesthetics, a more prolonged suppression using cryoneurolysis was considered. Patient remained free of ventricular arrhythmias for 5 months, an interval similar with the reported action of cryoneurolysis on the sensory nerves.

In conclusion, cryoneurolysis of the LSG appeared to be feasible and provide a prolonged blockade. Further research data are needed to elucidate the efficacy and safety of this technique in the management of ventricular arrhythmias.

**Conflict of interest:** none declared.

### References

1. Chatzidou S, Kontogiannis C, Tsilimigras DI, Georgiopoulos G, Kosmopoulos M, Papadopoulou E *et al*. Propranolol versus metoprolol for treatment of electrical storm in patients with implantable cardioverter-defibrillator. *J Am Coll Cardiol* 2018;**71**:1897–906.
2. Fudim M, Boortz-Marx R, Ganesh A, Waldron NH, Qadri YJ, Patel CB *et al*. Stellate ganglion blockade for the treatment of refractory ventricular arrhythmias: a systematic review and meta-analysis. *J Cardiovasc Electrophysiol* 2017;**28**:1460–7.
3. Ilfeld BM, Gabriel RA, Trescot AM. Ultrasound-guided percutaneous cryoneurolysis for treatment of acute pain: could cryoanalgesia replace continuous peripheral nerve blocks? *Br J Anaesth* 2017;**119**:703–6.